

Involvement of Epstein-Barr virus latent membrane protein 1 in disease progression in patients with idiopathic pulmonary fibrosis

K Tsukamoto, H Hayakawa, A Sato, K Chida, H Nakamura, K Miura

Abstract

Background—The role of Epstein-Barr virus (EBV) in idiopathic pulmonary fibrosis (IPF) is uncertain. A study was undertaken to detect the virus in IPF as well as to clarify the influence of EBV on the clinical features of the disease.

Methods—Twenty nine lung specimens were obtained from patients with IPF, as well as five specimens from patients with systemic sclerosis with pulmonary fibrosis (SSc) and 15 specimens from controls. EBV DNA and EBV latent membrane protein 1 (LMP1) were detected using the PCR method and immunohistochemical analysis, respectively.

Results—EBV DNA was detected in 24 of 25 patients with IPF (96%), in all five patients with SSc (100%), and in 10 of 14 controls (71%). The detection ratio was significantly higher in patients with IPF than in controls ($p = 0.047$, odds ratio (OR) = 9.60, 95% confidence interval (CI) 0.9 to 96.9). Immunohistochemical analysis revealed that cuboidal epithelial cells were positively stained with anti-LMP1 antibody in nine of the 29 lung specimens from IPF patients. In contrast, neither the patients with SSc nor the control subjects showed positive staining. In the follow up periods LMP1 positive patients with IPF died more frequently from respiratory failure than LMP1 negative patients (4/9 versus 1/20; $p = 0.022$, OR = 15.20, 95% CI 1.3 to 168.0).

Conclusions—EBV LMP1 positivity may be associated with more rapid disease progression in IPF.

(Thorax 2000;55:958-961)

Keywords: idiopathic pulmonary fibrosis; Epstein-Barr virus; latent membrane protein 1 (LMP1)

Idiopathic pulmonary fibrosis (IPF)/cryptogenic fibrosing alveolitis (CFA) is a chronic inflammatory disease with a poor prognosis. About half of the patients die of respiratory failure within five years.^{1,2} Although the aetiology of IPF remains unclear, serological studies of patients with IPF have suggested a possible role for the Epstein-Barr virus (EBV).³ In addition, as a result of an immunohistochemical study using monoclonal antibodies against EBV viral antigen, VCA and gp 340/220, Egan *et al*⁴ have recently suggested that EBV replicates in the pulmonary epithelial cells of some IPF patients. Controversy exists

as to whether EBV DNA can be detected in the lungs of patients with IPF; Stewart *et al*⁵ detected EBV DNA in the lungs of patients with IPF significantly more frequently than in those of normal controls whereas Wangoo *et al*⁶ failed to detect EBV DNA in the lungs of patients with IPF. In the present study we have used polymerase chain reaction (PCR) to detect EBV DNA in the lungs of these patients.

Latent membrane protein 1 (LMP1) is one of the EBV associated proteins and is expressed on the surface of EBV infected cells in the latent and replicating phases.^{7,8} Much attention has been paid to LMP1 because various functions have been revealed in recent decades. For example, LMP1 is essential for the *in vitro* transformation of human lymphocytes⁹ and rodent fibroblasts¹⁰ by EBV. It has also been reported that LMP1 influences the differentiation, morphology, and growth of human epithelial cell lines.^{11,12} Thus, it is possible that cells expressing LMP1 in the lungs may modulate the chronic inflammatory process in some pulmonary diseases. Here we present data which indicate that patients with IPF with positive staining for LMP1 have more progressive disease than LMP1 negative patients.

Methods

PATIENTS

Twenty nine patients with IPF (22 men) of mean age 58 years (range 38-72) were included in the study. The diagnosis of IPF was based on accepted criteria² which included clinical dyspnoea on exertion, cough, clubbing and bibasal crackles, radiological evidence of diffuse parenchymal infiltrates (peripheral reticulonodular pattern with a lower lobe predominance), compatible high resolution CT appearance,¹³ and physiologically restrictive lung function. All patients underwent open lung or videothoroscopic lung biopsy and were histologically diagnosed as having usual interstitial pneumonia (UIP). None were receiving medications such as steroids or immunosuppressive agents at the time of the study. Twenty one of the 29 patients were smokers and 18 had clubbing. The severity of the dyspnoea and chest radiographic abnormality at the initial examination was graded according to a score reported previously.¹⁴

Five patients with systemic sclerosis (SSc) with pulmonary fibrosis who fulfilled the American Rheumatism Association preliminary criteria for the diagnosis of SSc¹⁵ were also included in the study. They consisted of three men and two women of mean age 54 years

Second Division,
Department of
Internal Medicine,
Hamamatsu
University School of
Medicine,
Hamamatsu, Japan
K Tsukamoto
H Hayakawa
A Sato
K Chida
H Nakamura

Division of Pathology
K Miura

Correspondence to:
Dr K Tsukamoto, Division
of Pulmonary Medicine,
Fujieda Municipal General
Hospital, 4-1-11 Surugadai,
Fujieda, Shizuoka, 426-8677,
Japan

Received 21 October 1999
Returned to authors
31 January 2000
Revised manuscript received
25 July 2000
Accepted for publication
25 July 2000

(range 44–62). All patients underwent open lung or videothoroscopic lung biopsy to investigate their pulmonary disease.

All patients were followed up every month to investigate disease progression. The mean follow up period from the initial examination was 41 months (range 3–105) in patients with IPF and 54 months (range 15–94) in those with SSc. There was no significant difference in the follow up period between the two groups of patients.

As controls, tissue was taken from unaffected regions of lungs resected from 15 patients with primary lung tumours (nine patients) or bullae (six patients).

TISSUE PREPARATION

Lung tissue was fixed in 15% formaldehyde immediately after resection, then dehydrated and embedded in paraffin. Six sections (10 µm thick) from each block were collected in a single tube for PCR analysis. For immunohistochemical analysis 3 µm sections were placed onto glass slides pretreated with 3-aminopropyltriethoxysilane.

POLYMERASE CHAIN REACTION

The lung tissues were digested with proteinase K (0.2 mg/ml) and DNA was extracted using phenol/chloroform.

The PCR for EBV DNA was performed according to the method of Hashimoto *et al*¹⁶ with some modifications. Briefly, the PCR mixture contained 1 µg DNA, 5 µl of 10× Taq polymerase buffer (100 mM Tris-HCl, pH 8.8, 500 mM KCl, 15 mM MgCl₂, and 1% Triton X-100), 200 µmol/l of each deoxynucleotide, 25 pmol of EBV primers (5'-CACTTTAGAGCTCTGGAGGA-3' and 5'-TAAAGATAGCAGCAGCGCAG-3'), and 1.25 units of Taq polymerase (Nippon Gene Co Ltd, Tokyo, Japan) in a final volume of 50 µl. After initial incubation for three minutes at 94°C, 40 PCR cycles were performed which involved denaturing at 94°C for one minute, annealing at 57°C for 0.5 minute, and extension at 72°C for 1.5 minute. The amplified product was 153 bp in size. One µl of the first PCR product was subjected to the second PCR with a different primer set (5'-AACTTTAGAGGCGAATGGGC-3' and 5'-TAAAGATAGCAGCAGCGCAG-3'). The amplified product was 112 bp in size.

The PCR for β-globin was performed by the same procedure but with a different primer set (5'-GAAGAGCCAAGGACAGGTAC-3' and 5'-CAACTTCATCCACGTTCCACC-3')¹⁷ and some differences in the cycles (initial incubation for five minutes at 95°C followed by 35 cycles of denaturing at 95°C for 50 seconds, annealing at 56°C for 50 seconds, and extension at 72°C for 70 seconds).

PCRs performed with DNA extracted from EBV infected tissues and DNA amplified without a template were used as the positive and negative controls, respectively. The PCR products of EBV DNA were confirmed to be the expected sequences by restriction fragment length polymorphism analysis.

Table 1 Frequency of detection of EBV DNA in the lungs by PCR

IPF patients	24/25 (96%)*
SSc patients	5/5 (100%)
Normal controls	10/14 (71%)

IPF = idiopathic pulmonary fibrosis; SSc = systemic sclerosis. *p<0.05.

IMMUNOHISTOCHEMICAL ANALYSIS

Immunohistochemical analysis was performed using the streptavidin-biotin method with a SAB-PO kit (Nichirei Co Ltd, Tokyo, Japan). Anti-LMP1 monoclonal antibody (Dakopatts, Copenhagen, Denmark) was used at a dilution of 1:100. The antibody was detected with 3,3'-diaminobenzidine tetrahydrochloride and the specimens were counterstained with methyl green (Merck, Darmstadt, Germany).

For immunohistochemical controls, normal mouse immunoglobulin G was used as the first antibody. LMP1 positivity was evaluated by two observers (KT, HH) without knowledge of clinical data and there were no interobserver differences.

STATISTICAL ANALYSIS

Differences in frequency were assessed using Fisher's exact probability test, and the Mann-Whitney U test was used to compare quantitative data between the groups. A p value of <0.05 was considered to indicate statistical significance.

Results

DETECTION OF EBV DNA IN LUNG TISSUES BY PCR β-globin DNA was amplified in 25 of the 29 patients with IPF (86%), in all five of the patients with SSc (100%), and in 14 of the 15 controls (93%). Detection of EBV DNA was examined in the β-globin DNA positive cases.

EBV DNA was found in 24 of 25 patients with IPF (96%), in all five of the patients with SSc (100%), and in 10 of 14 controls (71%), indicating that EBV DNA was detected more frequently in the lungs of IPF patients than in controls (p = 0.047, odds ratio (OR) = 9.60, 95% confidence interval (CI) 0.9 to 96.9), table 1.

IMMUNOHISTOCHEMICAL ANALYSIS

Cuboidal lung epithelial cells were positively stained for LMP1 in nine of the 29 patients with IPF (31%). A representative example is shown in fig 1. In contrast, none of the patients with SSc nor the controls showed positive staining for LMP1.

CLINICAL CHARACTERISTICS OF LMP1 POSITIVE PATIENTS

To investigate the clinical influence of LMP1 positivity we carried out a further analysis. Table 2 summarises the clinical characteristics of LMP1 positive and LMP1 negative IPF patients and shows that there was no difference in clinical features at the initial examination between the two groups.

Follow up periods were similar for LMP1 positive and LMP1 negative patients. Eleven of the 29 patients were treated with oral prednisolone after lung biopsy and the remainder

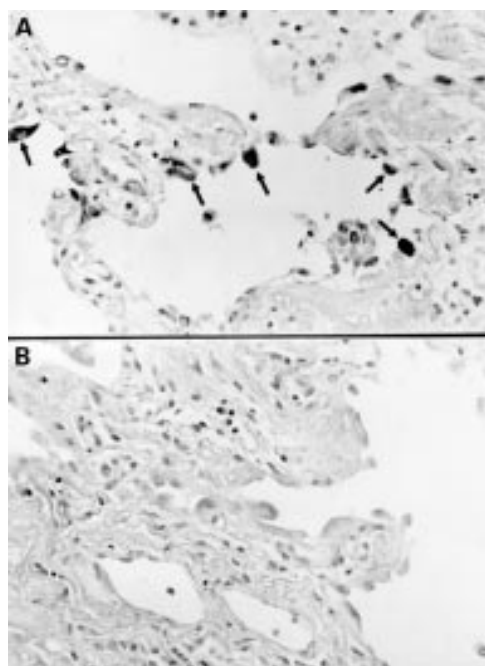


Figure 1 Photomicrographs of LMP1 immunostaining in lung tissue from a patient with IPF (methyl green; original magnification $\times 160$). (A) Staining with anti-LMP1 antibody. The cuboidal epithelial cells show positive staining (arrows). (B) Control staining.

did not receive treatment because they were clinically stable. The use of systemic steroids after lung biopsy was more frequent in LMP1 positive patients than in LMP1 negative patients ($p < 0.05$). Ten patients died during the follow up period. Causes of death included respiratory failure ($n=5$), lung cancer ($n=3$), respiratory infection ($n=1$), and heart failure ($n=1$). Death from respiratory failure was significantly higher in LMP1 positive patients than in LMP1 negative patients (4 of 9 (44%) versus 1 of 20 (5%), $p = 0.022$, OR = 15.20, 95% CI 1.3 to 168.0).

Table 2 Comparison of clinical characteristics between LMP1 positive and LMP1 negative patients with IPF

	LMP1+ (n=9)	LMP1- (n=20)	p value
Mean (range) age (years)	56 (38–63)	60 (47–72)	NS
Sex (M/F)	6/3	16/4	NS
Smoking history	6	15	NS
Dyspnoea score	5.8 (4.2)	4.8 (4.1)	NS
Clubbing	6	12	NS
Radiographic score	5.5 (1.0)	4.9 (1.2)	NS
Laboratory findings at initial examination:			
LDH (IU/l)	251 (101)	279 (118)	NS
CRP (mg/dl)	0.2 (0.2)	0.5 (0.7)	NS
Pao ₂ (kPa)	11.0 (0.9)	11.0 (1.5)	NS
%VC (%)	73.6 (33.4)	79.9 (19.7)	NS
Bronchoalveolar lavage cells (%)			
Macrophages	91.0 (10.0)	82.5 (24.2)	NS
Lymphocytes	4.7 (7.5)	13.0 (23.7)	NS
Neutrophils	6.6 (3.5)	5.8 (4.3)	NS
Eosinophils	0.5 (1.0)	1.9 (4.2)	NS
Mean (range) follow up period (mo)	42 (12–105)	41 (3–98)	NS
Steroid treatment	6 (67%)	5 (25%)	<0.05
Outcome			
Died	5 (55%)	5 (25%)	NS
Cause of death			
Respiratory failure	4 (44%)	1 (5%)	<0.05
Lung cancer	1 (11%)	2 (10%)	NS
Pulmonary infection	0	1 (5%)	NS
Heart failure	0	1 (5%)	NS

LDH = lactate dehydrogenase; CRP = C reactive protein; Pao₂ = arterial oxygen tension; VC = vital capacity.

Values are expressed as mean (SD) unless otherwise indicated.

In a follow up study of the patients with SSc all received D-penicillamine after the lung biopsy and none of them died of pulmonary fibrosis during the study period.

Discussion

This study found EBV DNA in the lungs of patients with IPF as well as controls. Only two reports investigating whether EBV DNA is present in lung tissue from IPF patients have been previously published.^{5,6} Wangoo *et al*⁶ failed to detect EBV DNA by PCR while Stewart *et al*⁵ successfully detected it. Different subjects and the use of different PCR procedures may be responsible for the discrepancy between these results and those found in our study. Like Stewart *et al*, we included an internal amplification control to ensure DNA extraction from paraffin blocks whereas Wangoo *et al* did not. In addition, Wangoo *et al* used a single step PCR method whereas we, like Stewart *et al*, used a two step PCR procedure to obtain higher sensitivity. We believe that EBV DNA can be detected in the lungs because of its ubiquitous nature, as suggested by Lung *et al*.¹⁸

Our data also indicated that the prevalence of EBV DNA was significantly higher in the affected lungs of IPF patients than in normal lung tissue from control subjects. This finding agreed with the previous data by Stewart *et al*⁵ who speculated that EBV might be involved in the pathogenesis of the disease. Although the role of EBV remains to be further clarified, it should be noted that EBV has been detected more frequently in several chronic pathological tissues than in the corresponding normal tissues, including synovial tissue in rheumatoid arthritis,¹⁹ salivary glands in Sjögren's syndrome,²⁰ and the lungs in lymphocytic interstitial pneumonia²¹ or rapidly progressive interstitial pneumonitis associated with polymyositis/dermatomyositis.¹⁷ These findings may collectively indicate that chronic inflammatory states are associated with an increase in the detection of this virus.

We found that LMP1 was positive in the cuboidal epithelial cells of the lungs from some patients with IPF, and that its positivity was significantly correlated with disease progression to respiratory failure. In contrast, neither the patients with SSc nor the control subjects showed positive results for LMP1 staining, and it was noted that the clinical course of the patients with SSc was quite stable during follow up. These results suggest that LMP1 expression by pulmonary epithelial cells infected with EBV leads to acceleration of lung inflammation and results in a poor clinical outcome in IPF. Although the mechanism underlying LMP1 expression by EBV infected cells in some patients with IPF remains uncertain, it is tempting to speculate possible explanations for our observation based on recent publications on LMP1. For example, LMP1 expression was reported to inhibit human epithelial cell differentiation,¹¹ to suppress p53 mediated apoptosis,²² and to upregulate HLA-DR²³ and ICAM-1 expression²⁴ in transfected cells,

which could possibly cause an alteration in the inflammatory response as well as impairment of tissue repair, resulting in fibrosis.

LMP1 staining was found to be indicative of disease activity and may be a useful finding for the management of IPF in which there is considerable heterogeneity in disease progression. Previously reported parameters for such clinical evaluation have included serum levels of lactate dehydrogenase (LDH),²⁵ KL-6,²⁶ and circulating immune complexes,²⁷ the lymphocyte²⁸ or eosinophil²⁹ count in bronchoalveolar lavage fluid, and histological evaluation for cellularity and fibrosis.^{2,30} As well as these parameters, LMP1 staining may indicate, to some degree, the disease activity or disease progression, although the sensitivity and accuracy of these remain to be further established.

In conclusion, using PCR we have detected EBV DNA in the lungs of patients with IPF as well as in those with SSc and control subjects, and we have shown that LMP1 positivity, measured by immunohistochemistry, is related to the prognosis of IPF. These results raise critical issues which need to be further investigated, such as the mechanism by which EBV produces LMP1 protein in some IPF patients and how this protein alters the function of cells in the lungs.

- 1 Crystal RG, Fulmer JD, Roberts WC, *et al.* Idiopathic pulmonary fibrosis. Clinical, histologic, radiographic, physiologic, scintigraphic, cytologic, and biochemical aspects. *Ann Intern Med* 1974;85:769–88.
- 2 Carrington CB, Gaensler EA, Coutu RE, *et al.* Natural history and treated course of usual and desquamative interstitial pneumonia. *N Engl J Med* 1978;298:801–9.
- 3 Vergnon JM, Vincent M, De The G, *et al.* Cryptogenic fibrosing alveolitis and Epstein-Barr virus: an association? *Lancet* 1984;ii:768–70.
- 4 Egan JJ, Stewart JP, Hasleton PS, *et al.* Epstein-Barr virus replication within pulmonary epithelial cells in cryptogenic fibrosing alveolitis. *Thorax* 1995;50:1234–9.
- 5 Stewart JP, Egan JJ, Ross AJ, *et al.* The detection of Epstein-Barr virus DNA in lung tissue from patients with idiopathic pulmonary fibrosis. *Am J Respir Crit Care Med* 1999;159:1336–41.
- 6 Wangoo AR, Shaw J, Diss TC, *et al.* Cryptogenic fibrosing alveolitis: lack of association with Epstein-Barr virus infection. *Thorax* 1997;52:888–91.
- 7 Liebowitz D, Wang D, Kieff E. Orientation and patching the latent infection membrane protein encoded by Epstein-Barr virus. *J Virol* 1986;58:233–7.
- 8 Gilligan K, Rajadurai P, Resnick L, *et al.* Epstein-Barr virus small nuclear RNAs are not expressed in permissively infected cells in AIDS-associated leukoplakia. *Proc Natl Acad Sci USA* 1990;87:8790–4.
- 9 Kaye K, Izumi KM, Kieff E. Epstein-Barr virus latent membrane protein 1 is essential for B-lymphocyte growth transformation. *Proc Natl Acad Sci USA* 1993;90:9150–94.
- 10 Wang D, Liebowitz D, Kieff E. An EBV membrane protein expressed in immortalized lymphocytes transforms established rodent cells. *Cell* 1985;43:831–40.
- 11 Dawson CW, Rickinson AB, Young LS. Epstein-Barr virus latent membrane protein inhibits human epithelial cell differentiation. *Nature* 1990;344:777–80.
- 12 Fahraeus R, Rymo L, Rhim JS, *et al.* Morphological transformation of human keratinocytes expressing the LMP-1 gene of Epstein-Barr virus. *Nature* 1990;345:447–9.
- 13 Tung KT, Wells AU, Rubens MB, *et al.* Accuracy of the typical computed tomographic appearances of fibrosing alveolitis. *Thorax* 1993;48:334–8.
- 14 Waters LC, King TE, Schwarz MI, *et al.* A clinical, radiologic and physiologic scoring system for the longitudinal assessment of patients with idiopathic pulmonary fibrosis. *Am Rev Respir Dis* 1986;133:97–103.
- 15 American Rheumatism Association. Preliminary criteria for the classification of systemic sclerosis (scleroderma): report of the Subcommittee for Scleroderma Criteria of the American Rheumatism Association Diagnostic and Therapeutic Criteria Committee. *Arthritis Rheum* 1980;23:581–90.
- 16 Hashimoto Y, Nawata Y, Kurasawa K, *et al.* Investigation of EB virus and cytomegalovirus in rapidly progressive interstitial pneumonitis in polymyositis/dermatomyositis by in situ hybridization and polymerase chain reaction. *Clin Immunol Immunopathol* 1995;77:298–306.
- 17 Saiki RK, Gelfand DH, Stoffel S, *et al.* Primer-directed enzymatic amplification of DNA with a thermostable DNA polymerase. *Science* 1988;239:487–91.
- 18 Lung ML, Lam WK, So SY, *et al.* Evidence that respiratory tract is major reservoir for Epstein-Barr virus. *Lancet* 1985; i:889–92.
- 19 Takei M, Mitamura K, Fujiwara S, *et al.* Detection of Epstein-Barr virus-encoded small RNA 1 and latent membrane protein 1 in synovial lining cells from rheumatoid arthritis patients. *Intern Immunol* 1997;9:739–43.
- 20 Wen S, Shimizu N, Yoshiyama H, *et al.* Association of Epstein-Barr virus (EBV) with Sjögren's syndrome. Differential EBV expression between epithelial cells and lymphocytes in salivary glands. *Am J Pathol* 1996;149:1511–7.
- 21 Andiman WA, Martin K, Rubinstein A, *et al.* Opportunistic lymphoproliferations associated with Epstein-Barr viral DNA in infants and children with AIDS. *Lancet* 1985;ii:1390–3.
- 22 Fries KL, Miller WE, Raab-Traub N. Epstein-Barr virus latent membrane protein 1 blocks p53-mediated apoptosis through the induction of the A20 gene. *J Virol* 1996;70:8653–9.
- 23 Zhang Q, Brooks L, Busson P, *et al.* Epstein-Barr virus (EBV) latent membrane protein 1 increases HLA class II expression in an EBV-negative B cell line. *Eur J Immunol* 1994;24:1467–70.
- 24 Wang D, Liebowitz D, Wang F, *et al.* Epstein-Barr virus latent infection membrane protein alters the human B-lymphocyte phenotype: deletion of the amino terminus abolishes activity. *J Virol* 1988;62:4173–84.
- 25 Matusiewicz SP, Williamson IJ, Sime PJ, *et al.* Plasma lactate dehydrogenase: a marker of disease activity in cryptogenic fibrosing alveolitis and extrinsic allergic alveolitis? *Eur Respir J* 1993;6:1282–6.
- 26 Kobayashi J, Kitamura S. KL-6: a serum marker for interstitial pneumonia. *Chest* 1995;108:311–5.
- 27 Dreisin RB, Schwarz MI, Theofilopoulos AN, *et al.* Circulating immune complexes in the idiopathic interstitial pneumonias. *N Engl J Med* 1978;298:353–7.
- 28 Watters LC, Schwarz MI, Cherniack RM, *et al.* Idiopathic pulmonary fibrosis. Pretreatment bronchoalveolar lavage cellular constituents and their relationships with lung histopathology and clinical response to therapy. *Am Rev Respir Dis* 1987;135:696–704.
- 29 Peterson MW, Monick M, Hunninghake GW. Prognostic role of eosinophils in pulmonary fibrosis. *Chest* 1987;92:51–6.
- 30 Crystal RG, Bitterman PB, Rennard SI, *et al.* Interstitial lung disease of unknown cause. Part II. *N Engl J Med* 1984;310:235–44.