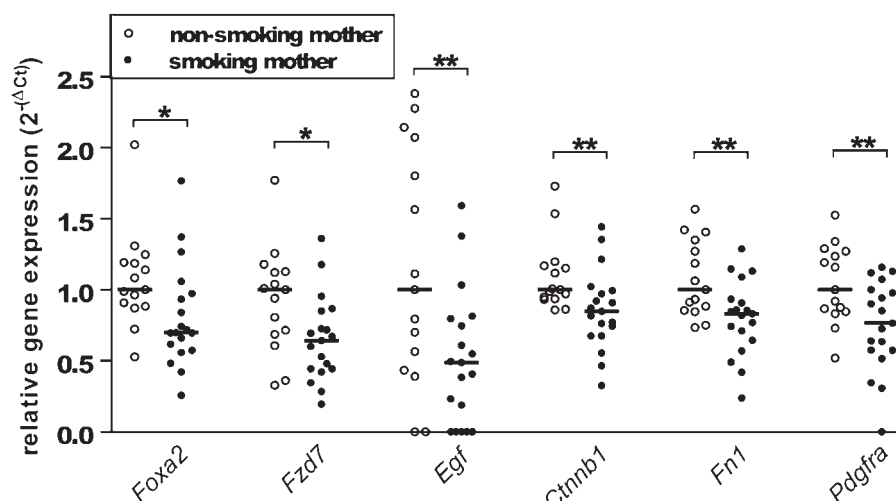


Figure 1 Relative gene expression in lung tissue of offspring from non-smoking mothers (open symbols) and smoking mothers (closed symbols). Data were normalised to GAPDH in order to correct for differences in input using the formula $\Delta Ct = Ct(GAPDH) - Ct(\text{gene of interest})$. The relative expression levels were calculated by $2^{-\Delta Ct}$ and levels are given relative to the non-smoking group. Medians from non-smoking mother group = 1. * $p < 0.05$, ** $p < 0.01$.



smoking had no effect on the expression levels of *Wnt-5* and *-7*, *Fzd-4* and *-10*, and *Pdgfa* (encoding wingless proteins 5 and 7, frizzled receptors 4 and 10 and platelet-derived growth factor, respectively) and expression of *Dkk1* (encoding dickkopf) was not detected. For an overview of the effects of maternal smoking during pregnancy on the Wnt pathway in the lung tissue of offspring, see figure 2 in the online supplement.

To our knowledge, this is the first report showing that maternal smoking during pregnancy decreases the expression of several genes involved in Wnt signalling in offspring. We propose that this relates to lung development as follows. *Foxa2* decreases alveolarisation and increases goblet cell hyperplasia when conditionally deleted from epithelial cells.² Interestingly, we have previously shown increased house dust mite-induced goblet cell hyperplasia in offspring from smoking mothers,¹ which could have been caused by decreased *Foxa2* expression. Furthermore, epidermal growth factor, β -catenin and the downstream Wnt target gene *Fn1* were also shown to be involved in branching morphogenesis of the fetal lung.^{3–5} In addition, *Fzd-7* is important in neovessel formation,⁶ while *Pdgfra* is involved in both neovessel formation and alveolarisation.⁷

Together, these findings provide a plausible argument for the effects of maternal smoking during pregnancy on Wnt- β -catenin signalling in the lungs of neonatal offspring. This may contribute to impaired lung development and an increased risk of developing asthma later in life. Moreover, Wnt signalling is involved in many other developmental processes that may thus be affected by maternal smoking during pregnancy. The relationship between defects in Wnt signalling and morphological/functional outcomes in lung tissue from offspring should therefore be investigated in more detail.

M J Blacqui re,¹ W Timens,¹ A van den Berg,¹ M Geerlings,¹ D S Postma,² M N Hylkema¹

¹Department of Pathology, University Medical Center Groningen, University of Groningen, The Netherlands; ²Department of Pulmonology, University Medical Center Groningen, University of Groningen, The Netherlands

Correspondence to Dr M Hylkema, Department of Pathology, University Medical Center Groningen, Hanzeplein 1, P O Box 196, 9700 RB Groningen, The Netherlands; m.n.hylkema@path.umcg.nl

► Figure 2 is published online only. To view these files please visit the journal online at (<http://thorax.bmj.com>).

Funding This work was supported by a grant from the European Commission as part of GABRIEL, a multidisciplinary study to identify the genetic and environmental causes of asthma in the European Community (contract no 018996).

Competing interests None.

Provenance and peer review Not commissioned; externally peer reviewed.

Accepted 9 July 2009

Thorax 2010;**65**:553–554.
doi:10.1136/thx.2009.120154

REFERENCES

- Blacqui re MJ, Timens W, Melgert BN, *et al*. Maternal smoking during pregnancy induces airway remodeling in mice offspring. *Eur Respir J* 2009;**33**:1133–40.
- Wan HJ, Kaestner KH, Ang SL, *et al*. *Foxa2* regulates alveolarization and goblet cell hyperplasia. *Development* 2004;**131**:953–64.
- Chinoy MR, Zgleszewski SE, Cilley RE, *et al*. Influence of epidermal growth factor and transforming growth factor beta-1 on patterns of fetal mouse lung branching morphogenesis in organ culture. *Pediatr Pulmonol* 1998;**25**:244–56.
- Maeda Y, Dave V, Whitsett JA. Transcriptional control of lung morphogenesis. *Physiol Rev* 2007;**87**: 219–44.
- Sakai T, Larsen M, Yamada KM. Fibronectin requirement in branching morphogenesis. *Nature* 2003;**423**:876–81.
- Dufourcq P, Leroux L, Ezan J, *et al*. Regulation of endothelial cell cytoskeletal reorganization by a secreted frizzled-related protein-1 and frizzled 4- and

frizzled 7-dependent pathway. *Am J Pathol* 2008;**172**:37–49.

- Bostrom H, Gritti-Linde A, Betsholtz C. PDGF-A/PDGF alpha-receptor signaling is required for lung growth and the formation of alveoli but not for early lung branching morphogenesis. *Dev Dyn* 2002;**223**:155–62.

Circulating endothelial stem cells are not decreased in pulmonary emphysema or COPD

Previous studies have suggested a role for an increased apoptosis of the endothelial cells in the pulmonary capillaries of the alveolar septa in the pathogenesis of human pulmonary emphysema.¹ In animal models, circulating endothelial stem cells, characterised by the concomitant expression of CD34+, CD133 and vascular endothelial growth factor receptor 2 (VEGF-R2), may contribute to the repair of lung damage.² However, it is unknown if a decrease in the blood of these stem cells contributes to the pathogenesis of pulmonary emphysema in humans. The aim of our study was to investigate by flow cytometry the number of total (CD34+) and endothelial stem (triple positive for CD34+/CD133/VEGF-R2) cells in the peripheral venous blood of current and former smokers of similar age, with or without pulmonary emphysema.

All the recruited subjects were free from concomitant diseases or drugs able to interfere with the number of circulating stem cells. Venous blood samples were obtained from 37 subjects (mean (SD) age 66.8 (1.4) years, 25M/12F, mean (SD) 33.11 (3.2) pack-years, 12 current and 25 ex-smokers). All former smokers had stopped smoking for more than 1 year. Twenty-two subjects (59.5%) had chronic obstructive pulmonary disease (COPD) according to the criteria of the Global Initiative for Chronic Obstructive Lung Disease guidelines³ (mean post-bronchodilator forced expiratory volume in

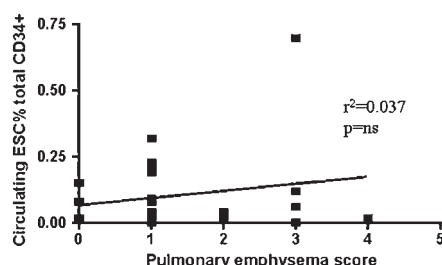


Figure 1 Correlation between number of circulating endothelial stem cells (ESC) expressed as a percentage of the total number (CD34+) of circulating stem cells, and high-resolution CT scan of the chest score of pulmonary emphysema.

1 s/forced vital capacity (FEV₁/FVC) ratio 56.8 (2.7%) whereas 39.5% (n = 15) had normal lung function (FEV₁/FVC ratio 77.1 (1.4%).

The presence and the severity of pulmonary emphysema was determined using high-resolution CT (HRCT) scans of the chest with density mask and the National Emphysema Treatment Trial Research Group score (0–4).⁴ The mean (SD) HRCT score was 1.7 (0.4). Blood sampling and flow cytometry were performed as previously described.⁵ Briefly, quantification of peripheral blood CD34+ cells was performed with double labelling with FITC-anti-CD45 and phycoerythrin-anti-CD34 monoclonal antibodies (Becton Dickinson, Milan, Italy) on a FACSCalibur flow cytometer (Becton Dickinson) according to standardised procedures. Enumeration of endothelial stem cells was performed as CD34 + cells co-expressing CD133 and VEGF-2. It was performed on immunomagnetically puri-

fied peripheral blood CD34+ cells (Miltenyi Biotech, Bologna, Italy) by triple labelling with peridinin chlorophyll protein-conjugated anti-CD34, phycoerythrin-conjugated anti-CD133 (Miltenyi Biotech) and unconjugated anti-VEGFR-2 (Santa Cruz Biotechnology, Milan, Italy), followed by FITC-conjugated swine anti-rabbit (Dako, Milan, Italy) as secondary reagent.

We found a significant correlation between the absolute number of circulating CD34+ cells and the absolute number of circulating endothelial stem cells ($r^2 = 0.593$, $p < 0.0001$; see figure 1 in online supplement). There was also a significant correlation between the percentage of circulating endothelial stem cells and the number of pack-years smoked ($r^2 = 0.42$, $p < 0.05$; see figure 2 in online supplement). No significant correlation was found between total and endothelial stem cell numbers and HRCT score of pulmonary emphysema (figure 1), lung function data or smoking status (current vs ex-smokers). These data indicate that the number of circulating endothelial stem cells is not related to the presence and/or severity of the pulmonary emphysema or the presence or absence of COPD.

G Caramori,¹ G M Rigolin,² F Mazzoni,¹ S Leprotti,³ P Campioni,³ A Papi¹

¹Centro di Ricerca su Asma e BPCO, University of Ferrara, Italy; ²Section of Hematology, University of Ferrara, Italy; ³Section of Radiology, University of Ferrara, Italy

Correspondence to Dr G Caramori, Centro di Ricerca su Asma e BPCO, University of Ferrara, Italy; gaetano.caramori@unife.it

► Additional figures are published online only. To view these files please visit the journal online at (<http://thorax.bmj.com>).

Competing interests None.

Ethics approval The study was approved by the local ethics committee of the University Hospital of Ferrara and written informed consent was obtained from each participant in accordance with the principles outlined in the Declaration of Helsinki.

Provenance and peer review Not commissioned; externally peer reviewed.

Accepted 14 August 2009

Thorax 2010;**65**:554–555.

doi:10.1136/thx.2009.121640

REFERENCES

1. Kasahara Y, Tuder RM, Cool CD, *et al*. Endothelial cell death and decreased expression of vascular endothelial growth factor and vascular endothelial growth factor receptor 2 in emphysema. *Am J Respir Crit Care Med* 2001;**163**:737–44.
2. Yamada M, Kubo H, Kobayashi S, *et al*. Bone marrow-derived progenitor cells are important for lung repair after lipopolysaccharide-induced lung injury. *J Immunol* 2004;**172**:1266–72.
3. Global Initiative for Chronic Obstructive Lung Disease (GOLD). *Global strategy for the diagnosis, management and prevention of chronic obstructive pulmonary disease*. NHLBI/WHO workshop report. NIH Publication No 2701A, March 2001 (last update 2008). <http://www.goldcopd.com> (accessed 9 June 2009).
4. National Emphysema Treatment Trial (NETT) Research Group. Patients at high risk of death after lung-volume-reduction surgery. *N Engl J Med* 2001;**345**:1075–83.
5. Valgimigli M, Rigolin GM, Fucili A, *et al*. CD34 + and endothelial progenitor cells in patients with various degrees of congestive heart failure. *Circulation* 2004;**110**:1209–12.

Images in Thorax

Massive thymic hyperplasia presenting with respiratory insufficiency in a 2-year-old child

A 2-year-old boy presented with fever, dry cough and dyspnoea for 3 days. Breath sounds were absent and thoracic percussion revealed dullness in the lower two-thirds of the left hemithorax. A chest x-ray showed almost complete opacification of these areas (figure 1). The boy was successfully treated with antibiotics for lower airways infection but tachypnoea persisted and the x-ray showed no change after 6 weeks. A CT scan was performed and showed a heterogeneous mass in the anterior mediastinum, predominantly on the left side, occupying most of the left hemithorax. This lesion showed areas of lower attenuation interspersed with areas of soft tissue attenuation (figure 2). The possibility of a germinative cell tumour was considered so α -fetoprotein and β -human chorionic gonadotropin were measured but were found to be within normal limits. A percu-

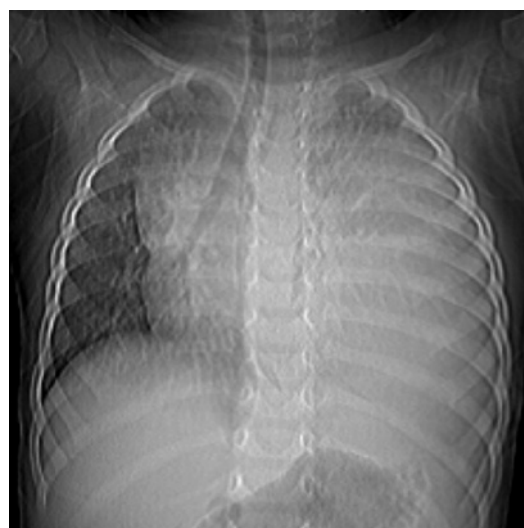

Figure 1 Chest x-ray showing opacification of the lower two-thirds of the left hemithorax. Part of the left upper lobe is still aerated.